

Iris pigment epithelial cysts

Category(ies): Glaucoma, Iris

Contributors: [Matt Ward, MD](#) (figure 1); [Thomas J.E. Clark, MD](#) (figure 2)

Photographer: Brice Critser, CRA (figure 2)

These cysts are fairly rare and classified as central (3%), midzonal (21%), peripheral (73%), and dislodged (3%). The majority of iris pigment epithelial cysts are benign and do not require any treatment.

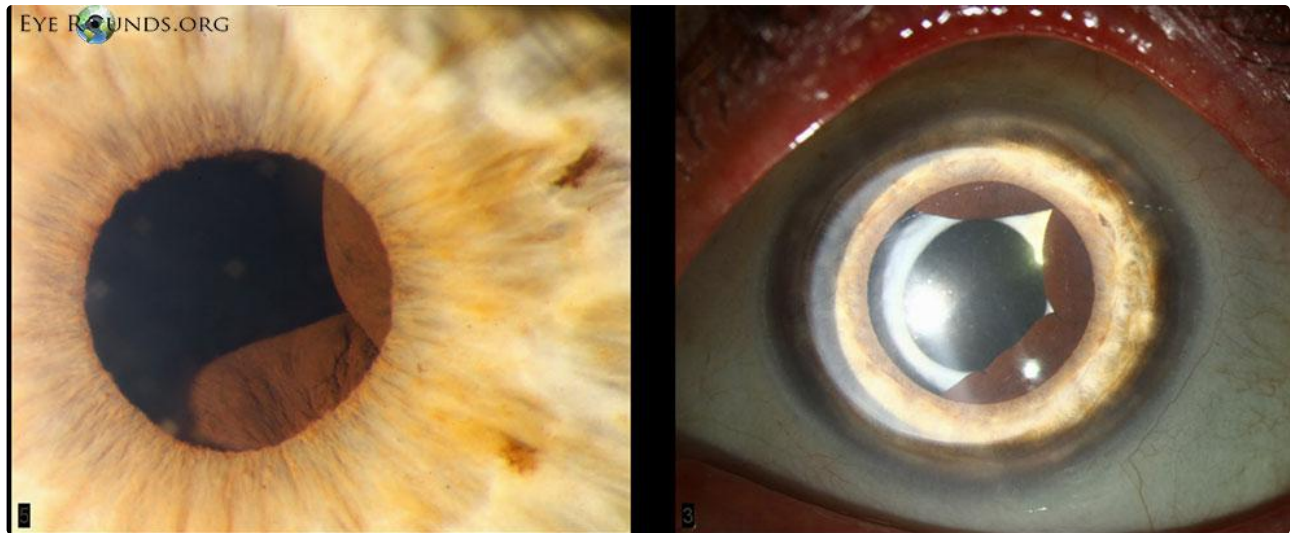


Figure 1

The central cysts above were seen in a 62-year-old female with a history of angle closure glaucoma (perhaps due to enlargement of the cysts).

[Enlarge](#)

[Download](#)

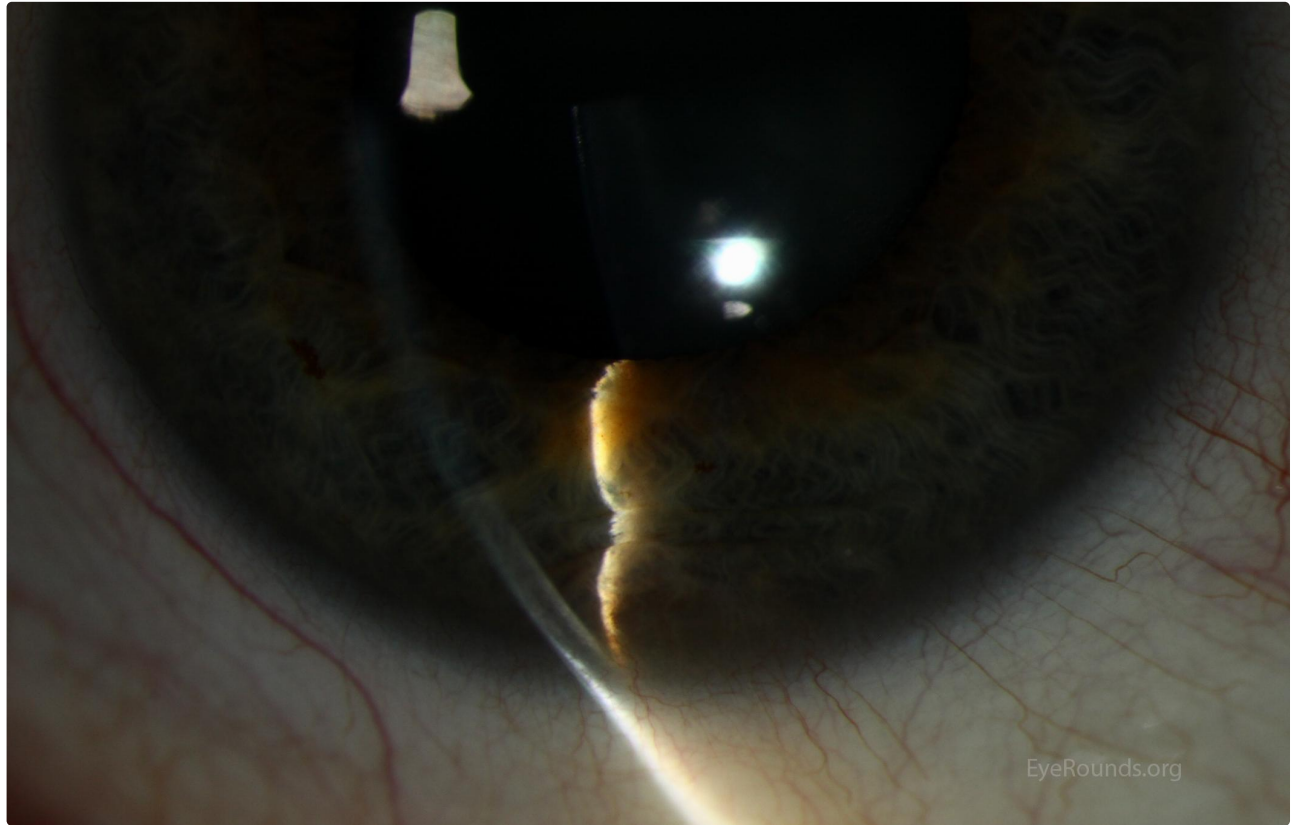


Figure 2A

On slit lamp examination , an elevation of the inferior iris is seen. It appears as the iris is being pushed or bowed forward from a posterior mass. Folds in the iris can be seen.

[Enlarge](#)

[Download](#)

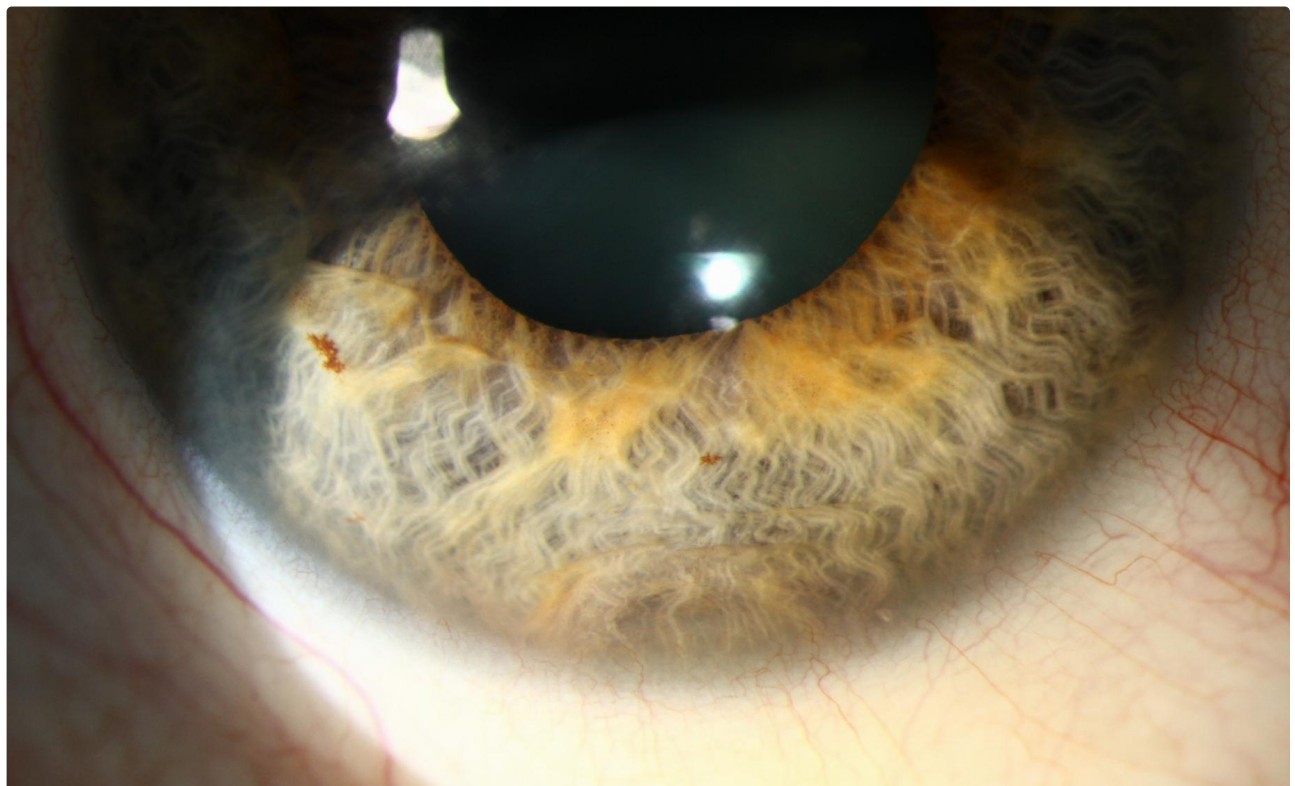


Figure 2B

On slit lamp examination , an elevation of the inferior iris is seen. It appears as the iris is being pushed or bowed forward from a posterior mass. Folds in the iris can be seen.

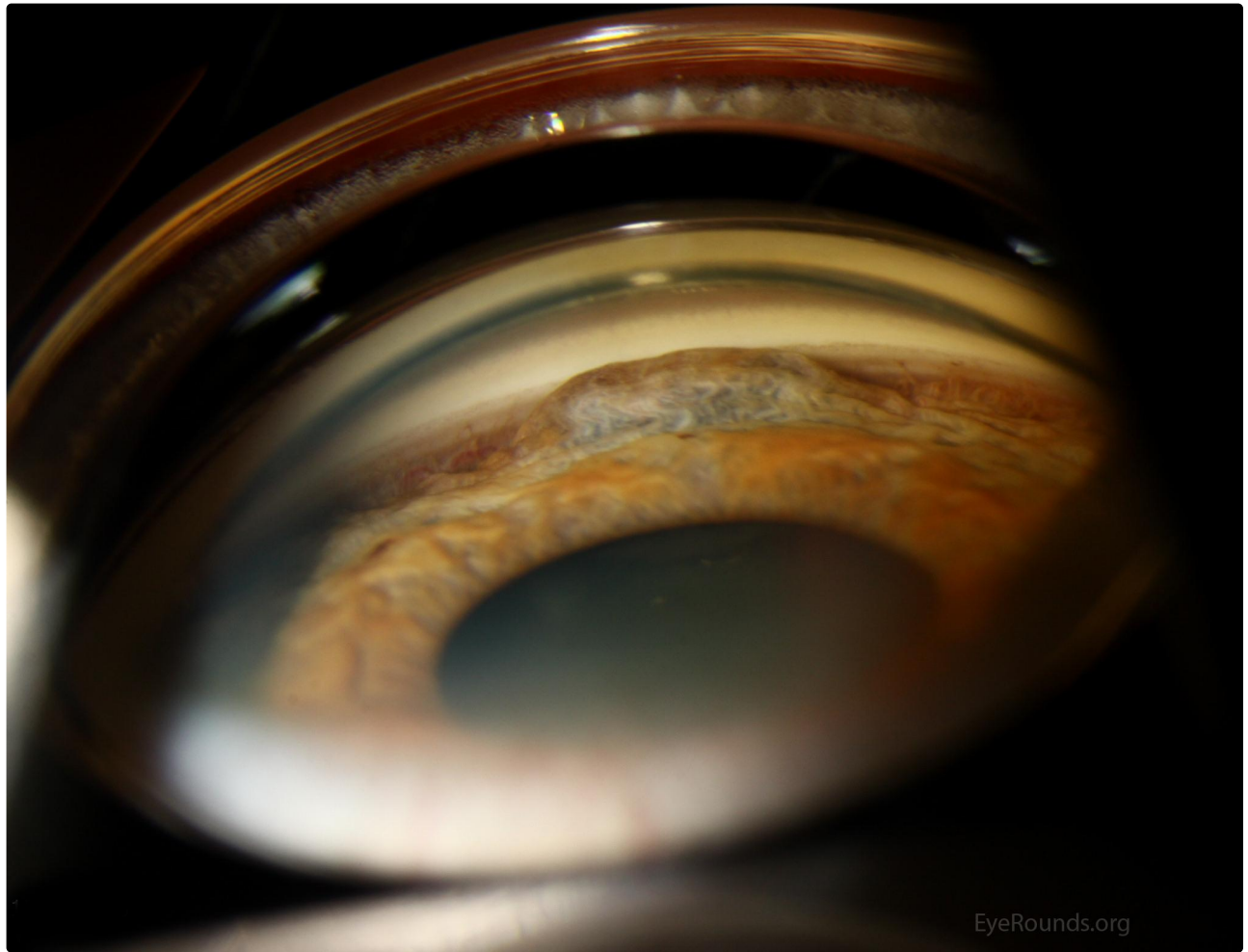
[Enlarge](#)
[Download](#)


Figure 2C

On gonioscopy examination (photo 2-C), the elevated, dome-shaped mass is apparent. With careful inspection, the pigment epithelial cyst can be seen through the pupil on the posterior surface of the iris. Also note the major arterial circle of the iris to the left of the cyst.

[Enlarge](#)
[Download](#)

Reference:

1. Lois N, Shields CL, Shields JA, Mercado G. [Primary cysts of the iris pigment epithelium. Clinical features and natural course in 234 patients.](#) Ophthalmology. 1998 Oct;105(10):1879-85.

Image Permissions:

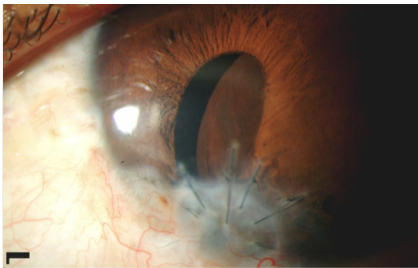


Ophthalmic Atlas Images by [EyeRounds.org](#), [The University of Iowa](#) are licensed under a [Creative Commons Attribution-NonCommercial-NoDerivs 3.0 Unported License](#).



Related Articles





[Related Case: Iris Cyst](#)

Address

University of Iowa
Roy J. and Lucille A. Carver College
of Medicine
Department of Ophthalmology and
Visual Sciences
200 Hawkins Drive
Iowa City, IA 52242

[Support Us](#)

Legal

Copyright © 2019 The University of
Iowa. All Rights Reserved
[Report an issue with this page](#)
[Web Privacy Policy](#) |
[Nondiscrimination Statement](#)

Related Links

[Cataract Surgery for Greenhorns](#)
[EyeTransillumination](#)
[Gonioscopy.org](#)
[Iowa Glaucoma Curriculum](#)
[Iowa Wet Lab](#)
[Patient Information](#)
[Stone Rounds](#)
[The Best Hits Bookshelf](#)

EyeRounds Social Media

Follow



Receive notification of new cases,
[sign up here](#)
[Contact Us](#)
[Submit a Suggestion](#)